

## Positioning of a Contextual Implant Along with a Sinus Lift with Smartbone® Microchips of Composite Heterologous-Synthetic Bone

Ilaria Zollino<sup>1</sup>, Giorgio Carusi<sup>2,3</sup>, Francesco Carinci<sup>1</sup>, Giuseppe Perale<sup>3,4</sup>

### Abstract

The present case reports the success rate after 8 months of follow-up in a sinus pneumatization case with maxillary sinus floor cortical bone loss due to 2.5 dental agenesis. Rehabilitation including the opportunity to insert a contextual implant during maxillary sinus lift surgery was planned, using SmartBone® Microchips heterologous bone inserted into the maxillary sinus. The newly developed bone substitute was designed starting from bovine bone derived mineral matrix, reinforced with bioresorbable aliphatic polymers and cell nutrients. SmartBone® Microchips showed a tight contact with the new bone and neither gaps nor fibrous tissues at the interface. No inflammation or foreign body reaction were observed, and these findings support the good biocompatibility of SmartBone® Microchips composite material. Moreover, new bone, thanks to its mechanical properties, consented to fix screw in combination with maxillary sinus floor elevation for a dental implant.

**Keywords:** Implant; case report; sinus pneumatisation; sinus lift; SmartBone® Microchips.

### Introduction

Since the first use of sinus grafting implant placement in the atrophic posterior maxilla, sinus grafting has become a predictable method to increase vertical bone height. The first graft material suggested for the reconstruction of bone defects was autografts bone. Theoretically, autografts bone possesses the pre-requisite properties for the successful incorporation of a grafting material and for bone healing, thanks to it being both osteoconductive and osteoinductive. So, it is considered the gold standard graft for bone reconstruction. The limitations of using autografts bone grafts concern the size of the donor site and risks of morbidity due to demanding surgery. Factors to be taken into account when choosing the donor site are the amount of bone required, the type (cortical vs. cancellous) of bone needed, the recipient site, and the expected biological behaviour (neovascularization and resorption). Donor sites can be extraoral or intraoral. The iliac crest, the calvaria, the ribs and the tibia are the most commonly described extraoral donor sites in the literature. Mandibular symphysis, mandibular ramus, infrazygomatic crest and maxillary tuberosity have been suggested as different intraoral donor sites.<sup>1</sup>

In order to simplify bone reconstruction by avoiding donor site surgery, increased surgical cost, limited amount of material, possible rapid bone resorption, and patient discomfort, the use of bone substitutes is obviously an attractive alternative. Several bone substitutes of biological and synthetic origins are available: biological ones can be allografts, i.e., from other humans or xenografts, i.e., from other species than humans (bovine derived hydroxyapatite). Fresh or untreated allograft are limited in use due to the presence of antigens, which may affect the immune response and trigger a rejection response. As with xenografts, allografts proteins are extracted for reasons of immunological safety. As a consequence, the osteoinductive properties disappear and the graft can only work as an osteoconductive scaffold.<sup>2</sup>

The current focus, thus, is on xenografts vs. synthetic devices: naturally derived materials provide structures extremely similar to living tissues such as stimulating a specific cellular response, which sometimes supersedes the advantages of synthetic polymers. Xenografts may also reduce the stimulation of chronic inflammation or immunological reactions and toxicity, often detected with synthetic polymers and minerals (such as e.g., bioglasses and bioceramics).<sup>3</sup>

On the other side, materials science, in conjunction with bio- and nano-technologies, can satisfy these requirements by developing novel grafting devices. In particular, bioresorbable scaffolds, as key artificial devices widely used in tissue engineering, aim to provide a desirable microenvironment that allows neo-tissue to be generated properly for repairing and replacing damaged tissues or organs. Indeed, synthetic polymers can be tuned in terms of composition, rate of degradation, mechanical and chemical properties.<sup>3,4</sup> For all these reasons, the goal of the current approach was to combine the biocompatibility and tissue integration of natural materials with the possibility to tune mechanical and physical properties typical of synthetic ones: composite grafts best mimic the real nature of healthy human bone, being rigid and elastic, compact but porous, dense but viable to cells and vessels.

A newly developed bone substitute, named SmartBone® (briefly SB), was design following a new concept of composite approach, starting from bovine bone derived mineral matrix, reinforced with bioresorbable aliphatic polymers and RGD-containing peptide fragments as cell nutrients. In this case report the SmartBone® Microchips, 1-2 mm in diameter, were used to achieve a sinus lift surgery with the placement of a contextual implant screw.

### Case report

A 43-year-old male patient (smoker) was referred to private practitioner for implant-supported prosthesis in a sinus

<sup>1</sup>Department of Morphology, Surgery and Experimental Medicine, University of Ferrara, Ferrara, Italy, <sup>2</sup>Private practitioner, Ponsacco, Italy, <sup>3</sup>Industrie Biomediche Insubri SA, Mezzovico-Vira, Switzerland, <sup>4</sup>Department of innovative Technologies, University for Applied Science and Art of Southern Switzerland, Manno, Switzerland. Correspondence: Dr. Francesco Carinci, email: crc@unife.it

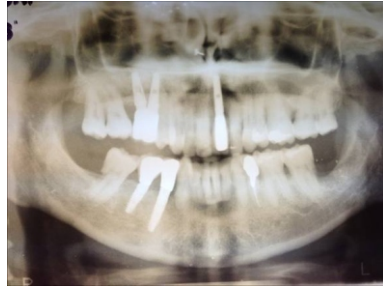


Figure 1: The orthopantomography shows the sinus pneumatization with loss of maxillary sinus floor cortical bone due to 2.5 dental agenesis

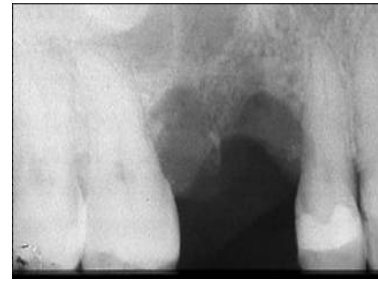

Figure 2: The radiography shows the bone defect

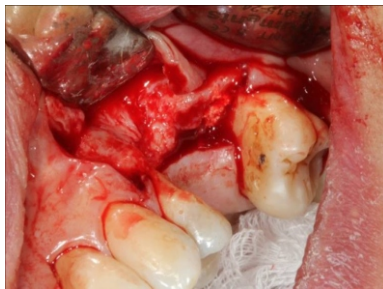

Figure 3: The elevated mucoperiosteal flap exposes the lateral bone aspect of the maxillary sinus

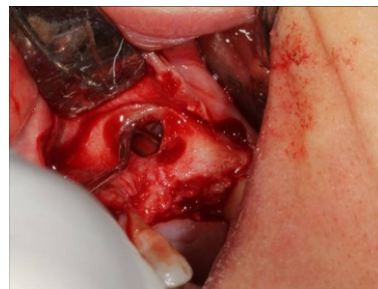

Figure 4: The periosteal elevator in the posterior/superior part of the created cavity prior to its filling with grafting material

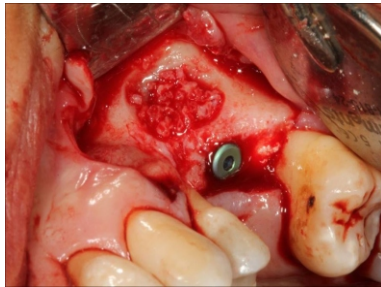


Figure 5: The grafted defect that allowed fixing screw for dental implant

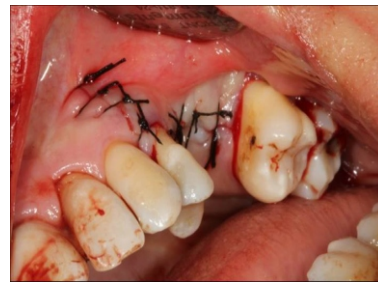

Figure 6: The mucoperiosteal flap replaced in position and sutured to cover the window opening

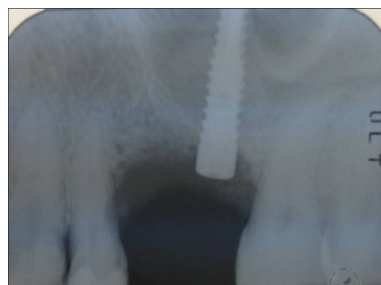

Figure 7: Checkup after surgery

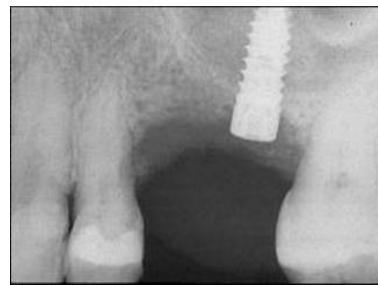


Figure 8: Radiography 4 months later shows good osseointegration together with new bone formation

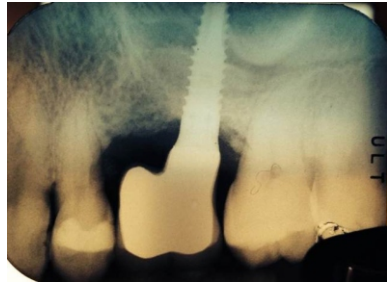

Figure 9: Radiography after 8 months shows good placement of the teeth

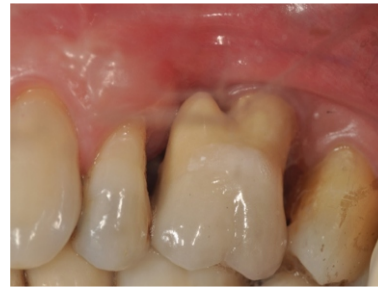

Figure 10: The final prosthetic result

pneumatization with loss of maxillary sinus floor cortical bone due to dental agenesis. Rehabilitation including the opportunity to insert a contextual implant during maxillary sinus lift surgery was planned, using SmartBone® Microchips heterologous bone molded and inserted into the maxillary sinus. The medical history does not note any particular contraindications for surgical therapy. The orthopantomography was performed where there is evidence of sinus pneumatization with loss of maxillary sinus floor cortical bone due to 2.5 dental agenesis (Figure 1).

The bone defect was studied and it is visible in the radiograph (Figure 2). This technique comprised the creation of an access to the maxillary sinus via a window through the lateral bone wall. A mucoperiosteal trapezoidal flap was raised after a midcrestal horizontal incision. The mucoperiosteal flap was elevated so as to expose the lateral bone aspect of the maxillary sinus (Figure 3). The osteotomy in the superior part of the window was carried out with a partial thickness approach so as to make the infraction of the window easier. However, a minimum size has been requested in order to have a comfortable access and for filling with graft material. So, the extent of the bone window to the sinus was marked by drilling with a medium size round bur. Dissection was performed carefully in order to avoid sinus membrane perforation using a periosteal elevator placed to the posterior/superior part of the created cavity prior to its filling with grafting material (Figure 4).

SmartBone® Microchips was mixed with patient blood and tailor modelled to obtain the desired shape once in situ. It was successfully grafted and allowed fixing screw for dental implant (Figure 5) covered with a commercial resorbable collagen membrane. The periosteal elevator was removed and the mucoperiosteal flap was replaced in position and sutured to cover the window opening (Figure 6). Check-up after surgery showed that everything was proceeding well (Figure 7): good osseointegration together with new bone formation were visible 4 months later from radiography (Figure 8) and the radiography after 8 months (Figure 9) showed good placement with patient teeth.

Regenerated ridges healed uneventfully. No post-operative complications were present after the ridge augmentation and at the time of the implantation surgery. Four months after scaffold implantation no evidence of serious adverse local, like inflammation, pain or dehiscence, was observed and no implanted material was identified in the regenerated sites.

From radiography it is visible that newly formed bone is similar to the surrounding tissue (Figure 9). The implanted

SmartBone® Microchips used in this study proved precisely handle to the necessary in order to obtain the desired shape for the specific patient bone defect. The success and realisation of the objective gives the patient, within a shorter time frame, the comfort of a rehabilitated set of teeth and the resulting advantages of this (Figure 10).

#### Discussion

The pneumatization is an important phenomenon that occurs after dental losses or with dental agenesis. If bone density and thickness can be explained, in part, by chewing forces applied, the pneumatization process is likely an architectural response to the muscles and chewing forces. The positive air pressure occurring during breathing inside the maxillary sinus can have an effect on maxillary sinus floor resorption. So, the presence of a reduced bone height demands an intervention on the maxillary sinus with the purpose to increase the bone amount available to implant insertion.<sup>5</sup>

Different materials are described on the literature to improve the bone volume on this region. These are fundamental important for the prognosis since different materials have different grades of osteogenesis.<sup>1</sup> For this reason, as said, most surgeons prefer to use autologous grafts as their first choice for osseous grafting or a mixture of autologous and biomaterial bone grafts for sinus surgeries. However, significant progresses in tissue engineering could yield more favorable outcomes than the current range of approaches used to repair bone defects.<sup>6</sup>

The newly developed bone substitute SmartBone® was designed following a new concept of composite approach, starting from bovine bone derived mineral matrix, reinforced with bioresorbable polymers and cell nutrients. The bovine derived matrix is mineral and mainly made of calcium hydroxyapatite (HA,  $\text{Ca}_5(\text{PO}_4)_3(\text{OH})$ ) that presents a chemical structure and a morphology resembling human bone.<sup>7,8</sup> However, its physical properties evidence rigid but not elastic structure which make it too fragile. In addition sterilization processes destroy its porous structure, widening it further than natural limits, and does not consent neither easy graft manufacturing nor cell adhesion. For these reasons bovine structure was reinforced with the addition of an elastic component in terms of polymer coating, losing thus fragility and reducing porosity to resemble healthy human bones. Finally, the addition of RGD-containing peptide fragments, increases the hydrophilicity of the scaffold with consequent higher cell attachment and thus enhan-

cing biocompatibility and osseointegration.<sup>8</sup>

The insertion of dental implants in combination with maxillary sinus floor elevation represented in this case report a predictable treatment method that showed high implant survival rates and low incidence of surgical complications. The new bone was observed in tight contact with the implanted SmartBone® Microchips material and neither gaps nor fibrous tissues were observed at the interface.

Pjetursson et al., in a systematic review to assess the survival rate of grafts and implants used for sinus floor elevation, reported an estimated annual failure rate of 3.48% translating into a 3-year implant survival rate of 90.1%.<sup>9</sup> So, these authors suggest that this treatment method is safe and predictable in relation to a simultaneous implant insertion. The difference in osseous formation within the grafted sinuses with mineralized bovine bone associated or not to absorbable or non absorbable membranes placed over the lateral window was studied by Wallace et al.<sup>10</sup> Differences were found in the histomorphometric analyses revealing that the groups with membranes showed a greater newly bone formation of 30% and in the group without membrane 14%. So, in according to these results it is suggested that the placement of membranes (absorbable or non absorbable) should be at the lateral window.

### Conclusion

The newly developed bone substitute SmartBone® Microchips showed in a patient with jaw cortical pavement defect a tight contact with the new bone and neither gaps nor fibrous tissues at the interface. No inflammation or foreign body reaction were observed, and these findings support the good biocompatibility of SmartBone® Microchips composite material. Moreover, new bone, thanks to its mechanical properties, consented to fix one screw in combination with maxillary sinus floor elevation for the dental implant. All these statements showed the good suitability of SmartBone® Microchips for alveolar defect repair in sinus lift procedure.

### Acknowledgements

This work was partially supported by FAR from the University of Ferrara (FC), Ferrara, Italy.

### References

1. Misch CE. Bone-grafting materials in implant dentistry. *Implant Dent* 1993;2:158-67.
2. Carinci F, Brunelli G, Zollino I, Franco M, Viscioni A, Rigo L, et al. Mandibles grafted with fresh-frozen bone: an evaluation of implant outcome. *Implant Dent* 2009;18:86-95.
3. Perale G, Rossi F, Sundstrom E, Bacchiega S, Masi M, Forloni G, Veglianese P. Hydrogels in spinal cord injury repair strategies. *ACS Chem Neurosci* 2011;2:336-45.
4. Arafat MT, Lam CX, Ekaputra AK, Wong SY, Li X, Gibson I. Biomimetic composite coating on rapid prototyped scaffolds for bone tissue engineering. *Acta Biomater* 2011;7:809-20.
5. Guilherme AS, Zavanelli RA, Fernandes JMA, Castro AT, Barros CA, Souza JEA, Cozac CD, Santos VA. Implantes osseointegráveis em áreas com levantamento do seio maxilare enxertos ósseos. *RGO* 2009;57:157-63.
6. Chen FM, An Y, Zhang R, Zhang M. New insights into and novel applications of release technology for periodontal reconstructive therapies. *J Control Release* 2011;149:92-110.
7. He J, Genetos DC, Leach JK. Osteogenesis and trophic factor secretion are influenced by the composition of hydroxyapatite/poly(lactide-co-glycolide) composite scaffolds. *Tissue Eng* 2010;16:127.
8. Kane RJ, Roeder RK. Effects of hydroxyapatite reinforcement on the architecture and mechanical properties of freeze-dried collagen scaffolds. *J Mech Behav Biomed* 2012;7:41-49.
9. Pjetursson BE, Tan WC, Zwahlen M, Lang NP. A systematic review of the success of sinus floor elevation and survival of implants inserted in combination with sinus floor elevation. *J Clin Periodontol* 2008;35:216-40.
10. Wallace SS, Froum SJ, Cho S-C, Elian N, Monteiro D, Kim BS, Tamo DP. Sinus Augmentation Utilizing Anorganic Bovine Bone (Bio-Oss) with Absorbable and Nonabsorbable Membranes Placed over the Lateral Window: Histomorphometric and Clinical Analyses. *Int J Perio Restor Dent* 2005;25:551-59.