Femoropatellar Osteoarthritis and Trochlear Femoral Bone Defect due to Giant Cell Tumor of the Knee: A Selected Patellofemoral Joint Arthroplasty and Reconstructive Technique

A Case Report

Andrea Conti, MD, Michele Boffano, MD, Pietro Pellegrino, MD, Nicola Ratto, MD, Luigi Sabatini, MD, and Raimondo Piana, MD

Investigation performed at AOU Città della Salute e della Scienza - Ospedale CTO, Torino, Italy

Abstract

Case: A 35-year-old man with a giant cell tumor involving the lateral condyle and trochlea of the right distal femur underwent curettage of the lesion and cement grafting, which resulted in symptomatic patellofemoral osteoarthritis after more than 4 years. A standard follow-up excluded recurrence, whereas infection was ruled out while investigating the symptoms. Finally, a patellofemoral resurfacing prosthesis was implanted while filling the bone defects with tantalum cones.

Conclusion: A "tailored" surgical technique with a selected patellofemoral joint arthroplasty could be used in oncologic setting to save further bone stock for possible revisions while permitting full and quick clinical recovery.

Giant cell tumor (GCT) is usually a benign primary bone tumor with aggressive characteristics. GCT has a significant incidence because it accounts for approximately 5% of all biopsy-analyzed primary bone tumors in adults and 15% of all biopsy-analyzed benign bone tumors[1]. Such lesion is known from the 19th century, and it

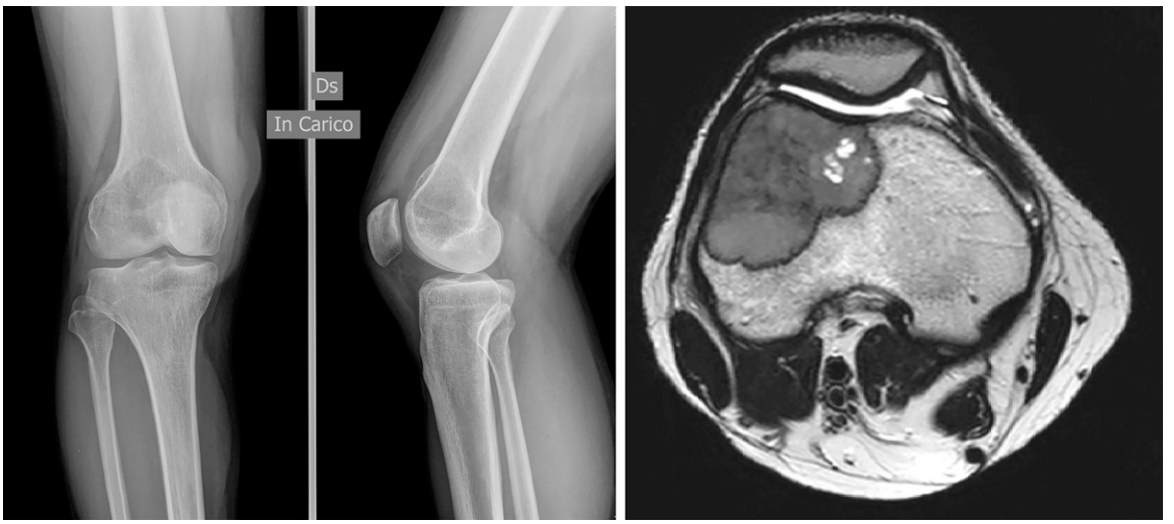

Fig. 1

On the left: anteroposterior and lateral radiograph of bone GCT at first diagnosis. On the right: axial magnetic resonance imaging scan of bone GCT at the same time. GCT = giant cell tumor.

Disclosure: The **Disclosure of Potential Conflicts of Interest** forms are provided with the online version of the article (http://links.lww.com/JBJSCC/B25).

Fig. 2
Three years FU of curettage and grafting of a bone GCT in anteroposterior and lateral radiograph. FU = follow-up, GCT = giant cell tumor.

consists of giant osteoclast-like cells in a hypercellular and vascularized stroma. Most frequently, it occurs in young adults (between 20 and 40 years of age) with a slight predominance in women and involves the metaphysis/epiphysis of a long bone. The most affected areas are distal femur, proximal tibia, and distal radius[2-9]. Campanacci et al.[10,11] classified GCTs into 3 types based on the radiographical appearance and the degree of bone destruction. Type I (quiescent) are small, well-defined intraosseus lesions; type II (active) are radiographically larger lesions, thinning and expanding the cortex without interrupting it; and type III (aggressive) lesions present undistinguished borders, destruction of the cortex extending through the periosteum, and the surrounding tissues.

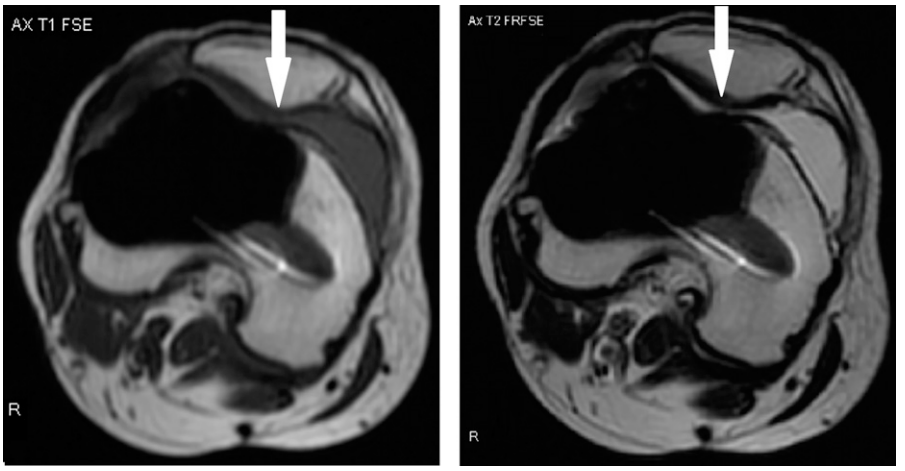

Fig. 3
Four years FU of curettage and grafting of a bone GCT in axial Magnetic resonance imaging study. White arrows point at the absence of articular cartilage of the trochlea. FU = follow-up, GCT = giant cell tumor.

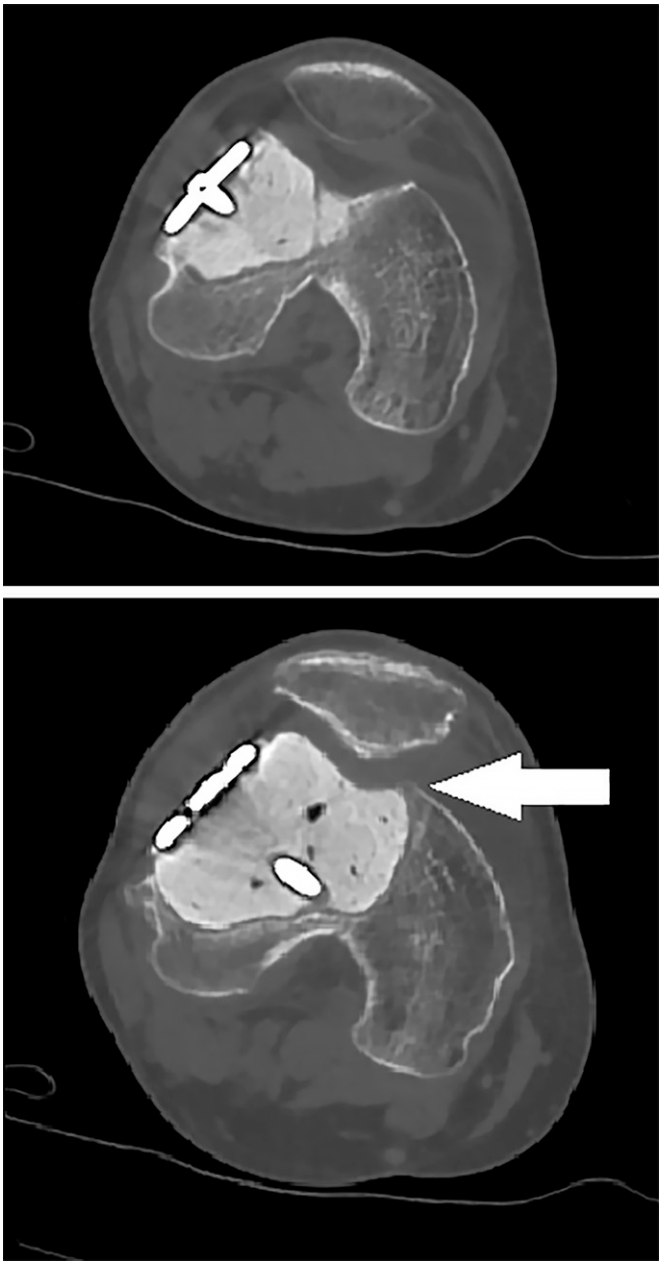

Fig. 4
Four years FU of curettage and grafting of a bone GCT in axial magnetic resonance imaging study. White arrow points at the cemented interface of the femoral trochlea. FU = follow-up, GCT = giant cell tumor.

Surgical treatment is the usual treatment. Denosumab has been described for inoperable GCT of the bone for its inhibition role on osteoclastogenesis. In addition, it has been described as a neoadjuvant agent to downstage the tumor, but recently, some authors claimed that such treatment may increase local recurrence[12]. Surgical options range from curettage and bone grafting or filling with polymethylmethacrylate (PMMA) to bone resection[1,13-23]. One of the possible complications of PMMA filling is long-term secondary osteoarthritis (OA) if cement is close to or submerging the joint surface. Whenever a knee is irreversibly damaged by OA and the patient is symptomatic, a total knee arthroplasty is the suggested solution and the same would be desirable even in oncological sequelae. Unfortunately, if residual bone stock is scarce, the use of megaprostheses either as a primary treatment of the neoplasm or to treat secondary OA combined with large bone defects after cement removal is not uncommon[24].

The aim of this manuscript is to present a technical note on how to solve this complication with a partial knee replacement.

The patient was informed that data concerning the case would be submitted for publication, and he provided consent.

Case Report

A 35-year-old man was diagnosed with a GCT of the bone of the right distal lateral femoral condyle (Fig. 1). The tumor

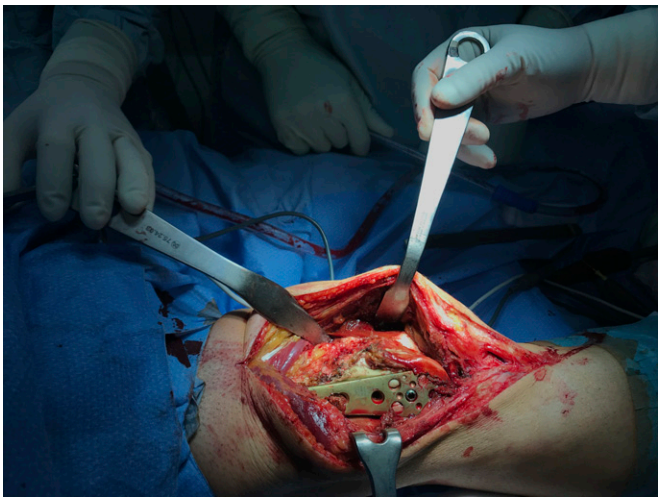

Fig. 5

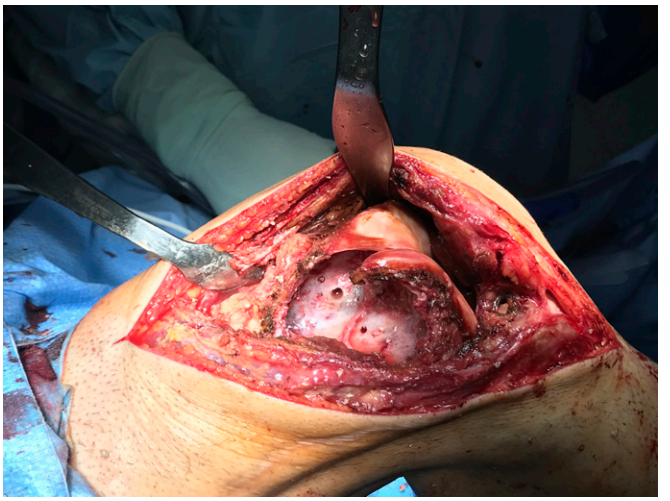

Fig. 6

Fig. 5 Before plate removal and cemental removal during revision surgery.
Fig. 6 After plate removal and cemental removal during revision surgery.

Fig. 7
On bench: cones and augments modeling during revision surgery.

was laterally approached and treated with intralesional curettage and adjuvant treatment with physical (high-speed burr and electrocautery) and chemical agents (phenol–alcohol). The residual cavity was injected with PMMA cement, also reconstructing the trochlear surface beneath the thin chondral layer. A lateral titanium plate was implanted for prophylactic fixation. Fifteen months later, the patient complained of slight patellar discomfort at maximum knee flexion, but he was still able to conduct common daily activities and normal working life (blacksmith). Thirty months after surgery, the patient reported constant pain and a consequent decrease of daily and working activities in a scenario of initial patellofemoral OA (Fig. 2) with recurrent hemarthrosis. The patient had a positive patellar grind test results and reported anterior pain at kneeling or prolonged sitting and in ascending/descending the stairs. Afterward, nonsteroidal anti-inflammatory drugs and physical therapies were prescribed. Because of low beneficial effects, 4 years and 2 months after primary surgery, a surgical revision treatment was proposed. Magnetic resonance imaging scan (Fig. 3) excluded local recurrence and confirmed a patellofemoral OA. Computed tomography scan (Fig. 4) confirmed the impingement of the patella with the cemented femoral trochlea. The knee was laterally approached, using the same previous surgical access. Previously implanted plate and screws and cement (Fig. 5) were removed, whereas multiple intraoperative cultures and immediate white blood count on synovial fluid (Fig. 6) were performed. The residual condylar bone gap was reconstructed with bone substitute blocks (SmartBone; IBI) wedged into TM cone augments (Zimmer Biomet) filled with morselized homologous bone graft, and the patellofemoral joint (PFJ) was resurfaced with an Oxinium and Journey PFJ arthroprosthesis, Smith & Nephew (Figs. 7 through 9). The patella was peripherally denervated, and osteophytes were removed. The patella was not resurfaced because there was an adequate patellofemoral congruency, normal shape, and appropriate thickness, and no evidence of bone exposition on the patellar side. In addition, the authors were concerned to prevent patellar overstuffing. Nonetheless, the patient was young, nonobese, and had no history of synovitis[25,26]. The patellar retinaculum was sutured tightly, and the patellar tracking double checked. The patient was discharged 4 days

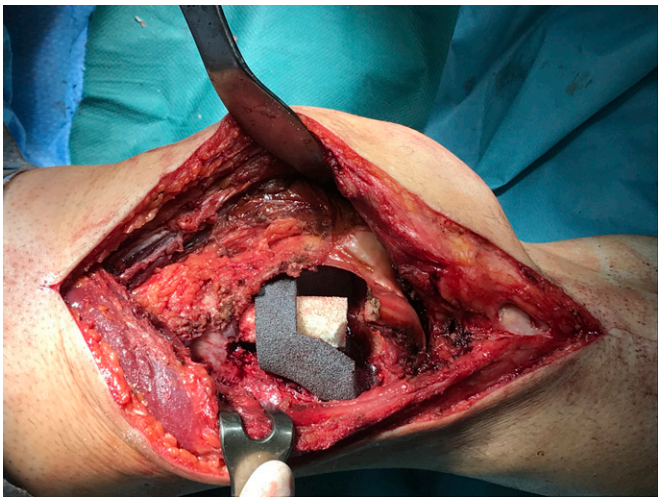

Fig. 8

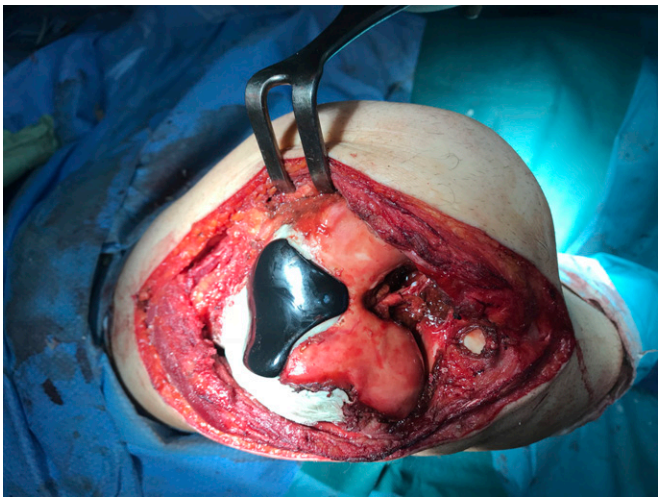

Fig. 9

Fig. 8 Implanting cones and augments in distal femur during revision surgery. **Fig. 9** After patellofemoral prosthesis positioning during revision surgery. Bone cement was used to place the trochlear resurfacing prosthesis, as advised in the surgical technique, and cover a small bone loss in the lateral wall of the distal femur.

Fig. 10
Above: 2 years FU of revision surgery in anteroposterior and lateral radiograph. At bottom: 2 years FU of revision surgery in patella view radiograph. FU = follow-up.

after the surgery with a bandage: weight-bearing was not permitted for 40 days and patellar passive and active motion exercises were allowed since week 4, whereas complete mobilization of the knee was allowed right away. After 8 weeks, the patient recovered full weight-bearing and mobility and started off with intense rehabilitation for muscle trophism recovery. Within 1 year, the patient fully recovered his abilities in both working life and sport activities. At the time of this manuscript submission, the patient had reached 2 and half years of follow-up from revision surgery. No pain was reported and full range of motion and satisfactory working and sport life was followed (Fig. 10).

Discussion

Distal femoral locally aggressive benign or low-grade malignant tumors are often treated at first with a local curettage. When the subchondral area or the articular cartilage are involved, secondary localized arthritis is 1 of the most common medium/long term nononcological complication[27]. Either the PFJ and/or the lateral or medial knee compartment can be affected. Despite the risk of developing OA, the treatment with curettage and PMMA filling is considered adjuvant to reduce local relapse while enabling at most the early detection of possible recurrences. Some authors claim that articular cartilage could be protected by positioning morselized bone graft beneath the articular cartilage, others prefer to suture cartilage above autologous bone graft or to use an osteoarticular allograft[28-32]. There are still controversies about the potential arthrogenic effect on cartilage after curettage and cementing, especially in juxta-articular tumors. This was invalidated by a study conducted by Von Steyern in 2007[33], which noted no osteoarthritic development at 9 years of follow-up.

The definitive treatment for OA is a total joint replacement with a total knee arthroplasty; on the other hand, a megaprosthesis could solve both problems of OA and residual bone defect from cement removal. Instead, a selected PFJ arthroplasty, in combination with bone gap filling with tantalum cones and bone synthetic blocks and homologous bone, preserves bone stock along with ligaments and menisci for a possible further revision surgery. Monocompartmental or bicompartmental knee replacement is supported by a strong literature even if strict indications are universally recognized[34-36]. Pain control is usually successfully achieved when the worn articular surfaces are replaced. This solution is applicable also to distal femoral postoncological defects or complications. The advantages of avoiding the use of a megaprosthesis are represented by cheaper costs, easier future revisions with a residual bone stock, better joint function because of the preservation of ligaments and menisci, and addressing only the replacement of the symptomatic area. This solution used prosthetic and nonprosthetic materials available off the shelves that can be adapted intraoperatively[37-39]. Tantalum is isoelastic with bone and minimizes stress shielding. It allows osteointegration while filling bone defects and allowing immediate tolerance of physiologic loads. Tantalum helps bone ingrowth and minimizes resorption. Furthermore, PMMA carries along the exothermic reaction that is desirable as an adjuvant in a GCT of the first bone surgery but can contribute to osteonecrosis and resorption[40]. A custom-made solution could represent an option with higher costs and long production times[41]. On the other side, this solution should not be suggested during the first years from tumor diagnosis because a prosthesis can masquerade a local recurrence. On the contrary, in elderly symptomatic patients with limited functional requirements, a conventional and stable total knee replacement can represent a stable and definitive alternative.

A solution with a selected PFJ prosthesis addresses the prosthetic replacement only to the symptomatic area. It presents the risk for a medium to long-term failure but theoretically allows conservative further prosthetic revisions.

Conclusion

Even if this surgery seems to score great biomechanical and clinical results, it brings along a high technical complexity and a steep learning curve. In oncological patients, a surgical procedure cannot be standardized and it needs to be "tailored" to the individual and accurately planned preoperatively. Furthermore, a key for success is a careful selection of the patient. Such procedures should be performed by expert knee and oncological surgeons in a referral center. ■

Andrea Conti, MD[1,2]
Michele Boffano, MD[2]
Pietro Pellegrino, MD[2]
Nicola Ratto, MD[2]
Luigi Sabatini, MD[3]
Raimondo Piana, MD[2]

[1]University of Torino, Torino, Italy

[2]AOU Città della Salute e della Scienza di Torino—Ospedale CTO, Department of Oncological and Reconstructive Orthopaedics, Torino, Italy

[3]AOU Città della Salute e della Scienza di Torino—Ospedale CTO, Department of Orthopaedics and Traumatology, Torino, Italy

E-mail address for M. Boffano: michele.boffano@gmail.com

ORCID iD for A. Conti: 0000-0003-0290-2780
ORCID iD for M. Boffano: 0000-0003-0775-1168
ORCID iD for P. Pellegrino: 0000-0002-3069-0749
ORCID iD for N. Ratto: 0000-0001-7502-1576
ORCID iD for L. Sabatini: 0000-0003-4956-1303
ORCID iD for R. Piana: 0000-0002-7651-4599

References

1. Klenke FM, Wenger DE, Inwards CY, Rose PS, Sim FH. Giant cell tumor of bone: risk for recurrence. Clin Orthop Relat Res. 2011;469(2):591-9.
2. Cooper AS, Travers B. Surgical Essays. London: Cox Longman & Co; 1818.178-9.
3. Jaffe HL, Portis RB. Giant cell tumor of bone. Its pathologic appearance, grading. Supposed variants and treatment. Arch Pathol. 1940;30:993.
4. Niu X, Zhang Q, Hao L, Ding Y, Li Y, Xu H, Liu W. Giant cell tumor of the extremity: retrospective analysis of 621 Chinese patients from one institution. J Bone Joint Surg Am. 2012. 94(5):461-7.
5. Kivioja AH, Blomqvist C, Hietaniemi K, Trovik C, Walloe A, Bauer HC, Jorgensen PH, Bergh P, Follerås G. Cement is recommended in intralesional surgery of giant cell tumors: a Scandinavian Sarcoma Group study of 294 patients followed for a median time of 5 years. Acta Orthop. 2008. 79(1):86-93
6. Turcotte RE, Wunder JS, Isler MH, Bell RS, Schachar N, Masri BA, Moreau G, Davis AM; Canadian Sarcoma Group. Giant cell tumor of long bone: a Canadian Sarcoma Group study. Clin Orthop Relat Res. 2002;397:248-58.
7. Kay RM, Eckardt JJ, Seeger LL, Mirra JM, Hak DJ. Pulmonary metastasis of benign giant cell tumor of bone. Six histologically confirmed cases, including one of spontaneous regression. Clin Orthop Relat Res. 1994(302):219-30.
8. Kitano K, Shiraishi T, Okabayashi K, Iwasaki A, Kawahara K, Shirakusa T. A lung metastasis from giant cell tumor of bone at eight years after primary resection. Jpn J Thorac Cardiovasc Surg. 1999;47(12):617-20.
9. Bertoni F, Present D, Sudanese A, Baldini N, Bacchini P, Campanacci M. Giant-cell tumor of bone with pulmonary metastases. Six case reports and a review of the literature. Clin Orthop Relat Res. 1988(237):275-85.
10. Campanacci M, Giunti A, Olmi R. Giant-cell tumours of bone: a study of 209 cases with long term follow up in 130. Ital J Orthop Traumatol. 1975;1:247-77.
11. Campanacci M, Baldini N, Boriani S, Sudanese A. Giant-cell tumor of bone. J Bone Joint Surg Am. 1987;69(1):106-14.
12. Errani C, Tsukamoto S, Leone G, Righi A, Akahane M, Tanaka Y, Donati DM. Denosumab may increase the risk of local recurrence in patients with giant-cell tumor of bone treated with curettage.J Bone Joint Surg Am. 2018;100(6):496-504.
13. Vidyadhara S, Rao SK. Techniques in the management of juxta-articular aggressive and recurrent giant cell tumors around the knee. Eur J Surg Oncol. 2007; 33:243-51.
14. Klenke FM, Wenger DE, Inwards CY, Rose PS, Sim FH. Recurrent giant cell tumor of long bones: analysis of surgical management. Clin Orthop Relat Res. 2011;469: 1181-7

15. Arbeitsgemeinschaft Knochentumoren, Becker WT, Dohle J, Bernd L, Braun A, Cserhati M, Enderle A, Hovy L, Matejovsky Z, Szendroi M, Trieb K, Tunn PU. Local recurrence of giant cell tumor of bone after intralesional treatment with and without adjuvant therapy. J Bone Joint Surg Am. 2008;90:1060-7.

16. Balke M, Schremper L, Gebert C, Ahrens H, Streitbuerger A, Koehler G, Hardes J, Gosheger G. Giant cell tumor of bone: treatment and outcome of 214 cases. J Cancer Res Clin Oncol. 2008;134:969-78.

17. Lackman RD, Hosalkar HS, Ogilvie CM, Torbert JT, Fox EJ. Intralesional curettage for grades II and III giant cell tumors of bone. Clin Orthop Relat Res. 2005;438: 123-7.

18. Blackley HR, Wunder JS, Davis AM, White LM, Kandel R, Bell RS. Treatment of giant-cell tumors of long bones with curettage and bone-grafting. J Bone Joint Surg Am. 1999;81:811-20.

19. Goldenberg RR, Campbell CJ, Bonfiglio M. Giant-cell tumor of bone. An analysis of two hundred and eighteen cases. J Bone Joint Surg Am. 1970;52:619-64.

20. Algawahmed H, Turcotte R, Farrokhyar F, Ghert M. High-speed burring with and without the use of surgical adjuvants in the intralesional management of giant cell tumor of bone: a systematic review and meta-analysis. Sarcoma 2010;2010: 586090.

21. Malek F, Krueger P, Hatmi ZN, Malayeri AA, Faezipour H, O'Donnell RJ. Local control of long bone giant cell tumor using curettage, burring and bone grafting without adjuvant therapy. Int Orthop. 2006;30:495-8.

22. Zuo D, Zheng L, Sun W, Fu D, Hua Y, Cai Z. Contemporary adjuvant polymethyl methacrylate cementation optimally limits recurrence in primary giant cell tumor of bone patients compared to bone grafting: a systematic review and meta-analysis. World J Surg Oncol. 2013;11:156.

23. Nelson DA, Barker ME, Hamlin BH. Thermal effects of acrylic cementation at bone tumour sites. Int J Hyperthermia. 1997;13:287-306.

24. Yu XC, Xu M, Song RX, Fu ZH, Liu XP. Long-term outcome of giant cell tumors of bone around the knee treated by en bloc resection of tumor and reconstruction with prosthesis. Orthop Surg. 2010;2(3):211-7.

25. Abdel MP, Parratte S, Budhiparama NC. The patella in total knee arthroplasty: to resurface or not is the question. Curr Rev Musculoskelet Med. 2014; 7(2):117-24.

26. Bracey DN, Brown ML, Beard HR, Mannava S, Nazir OF, Seyler TM, Lang JE. Effects of patellofemoral overstuffing on knee flexion and patellar kinematics following total knee arthroplasty: a cadaveric study. Int Orthop. 2015;39(9):1715-22.

27. Farfalli GL, Slullitel PA, Muscolo DL, Ayerza MA, Aponte-Tinao LA. What happens to the articular surface after curettage for epiphyseal chondroblastoma? A report on functional results, arthritis, and arthroplasty. Clin Orthoprelat Res. 2017;475(3): 760-6.

28. Aboulafia AJ, Rosenbaum DH, Sicard-Rosenbaum L, Jelinek JS, Malawer MM. Treatment of large subchondral tumors of the knee with cryosurgery and composite reconstruction. Clin Orthop Relat Res. 1994;(307):189-99.

29. Sawa M, Nakasa T, Ikuta Y, Yoshikawa M, Tsuyuguchi Y, Kanemitsu M, Ota Y, Adachi N. Outcome of autologous bone grafting with preservation of articular cartilage to treat osteochondral lesions of the talus with large associated subchondral cysts. Bone Joint J. 2018;100-B(5):590-5.

30. Tsuchiya H, Abdel-Wanis ME, Tomita K. Biological reconstruction after excision of juxta-articular osteosarcoma around the knee: a new classification system. Anticancer Res. 2006;26(1B):447-53.

31. Muramatsu K, Ihara K, Taguchi T. Treatment of giant cell tumor of long bones: clinical outcome and reconstructive strategy for lower and upper limbs. Orthopedics. 2009;2(7):491.

32. Ayerza MA, Aponte-Tinao LA, Farfalli GL, Restrepo CA, Muscolo DL. Joint preservation after extensive curettage of knee giant cell tumors. Clin Orthop Relat Res. 2009;467:2845-51.

33. von Steyern FV, Kristiansson I, Jonsson K, Mannfolk P, Heinegård D, Rydholm A. Giant-cell tumour of the knee: the condition of the cartilage after treatment by curettage and cementing. J Bone Joint Surg Br. 2007;89(3):361-5.

34. Ma JX, He WW, Kuang MJ, Sun L, Lu B, Wang Y, Ma XL. Efficacy of bicompartmental knee arthroplasty (BKA) for bicompartmental knee osteoarthritis: a meta analysis. Int J Surg. 2017;46:53-60.

35. Sabatini L, Giachino M, Risitano S, Atzori F. Bicompartmental knee arthroplasty. Ann Transl Med. 2016;4(1):5.

36. Parratte S, Ollivier M, Lunebourg A, Abdel MP, Argenson JN. Long-term results of compartmental arthroplasties of the knee: long term results of partial knee arthroplasty. Bone Joint J. 2015;97-B(10 suppl A):9-15.

37. Potter GD, Abdel MP, Lewallen DG, Hanssen AD. Midterm results of porous tantalum femoral cones in revision total knee arthroplasty. J Bone Joint Surg Am. 2016;98(15):1286-91

38. Nikolaus OB, Abdel MP, Hanssen AD, Lewallen DG. Porous tantalum femoral metaphyseal cones for large femoral bone defects in revision total knee arthroplasty. JBJS Essent Surg Tech. 2017;7(2):e17.

39. Divano S, Cavagnaro L, Zanirato A, Basso M, Felli L, Formica M. Porous metal cones: gold standard for massive bone loss in complex revision knee arthroplasty? A systematic review of current literature. Arch Orthop Trauma Surg. 2018;138(6):851-63.

40. Kim EG, Patel NK, Chughtai M, Elmallah RD, Delanois RE, Harwin SF, Mont MA. Tantalum cones in revision total knee arthroplasty. J Knee Surg. 2016;29(8):621-6.

41. Natarajan MV, Prabhakar R, Mohamed SM, Shashidhar R. Management of juxta articular giant cell tumors around the knee by custom mega prosthetic arthroplasty. Indian J Orthop. 2007;41(2):134-8.