

Evaluation of custom made xenogenic bone grafts in mandibular alveolar ridge augmentation versus particulate bone graft with titanium mesh

Original
Article

Mohammed S. Abuelnaga, Nader N. Elbokle, Mohammed M. Khashaba

Department of Oral and Maxillofacial Surgery, Faculty of Oral and Dental Medicine, Cairo University, Cairo, Egypt.

ABSTRACT

Aim: This study was to evaluate clinically and radiographically the volume changes of alveolar ridge grafting using customized xenogenic bone graft.

Materials and Methods: A total of 12 patients with mandibular horizontal and vertical alveolar ridge defects ≥ 3 mm were selected. They were divided into 2 groups: Group I (Test Group) included 6 patients in which mandibular alveolar ridges were reconstructed with customized Xenogenic bone graft Smartbone (IBI S.A., Switzerland). Group II (Control Group) included 6 patients in which mandibular alveolar ridges were reconstructed with particulate Xenogenic bone (Smart bone, IBI S.A., Switzerland) grafting to posterior mandibular ridge with titanium mesh was performed. Volume analysis of the changes in alveolar ridge in both Groups were obtained before and four months after the procedure using CBCT. Densitometric analysis of the Postoperative bone formed and compared with native bone. .

Results: Four months postoperatively. Measurements made on cone-beam computerized tomograms, four months postoperative showed significance increase in bone volume by 40 % in the area of newly formed bone in Group I (Customized bone) compared with 23% in Control Group. Statistical significant changes was found in the density of newly formed bone four months post-operatively in both Groups, however there was no significant difference in bone density postoperatively between Group I (customized Bone) and Group II (Control).

Conclusion: According to the results, the treatment of defective alveolar ridge augmentation of the mandibular ridge with customized xenogenic bone graft Smartbone (IBI S.A., Switzerland) is successful and produces results consistent with the control Group.

Key Words: Alveolar ridge defect, bone substitute, CAD/CAM, cone beam computed tomography, customized graft.

Received: 28 June 2018, **Accepted:** 16 August 2018

Corresponding Author: Mohammed El-Said Abuelnaga, Department of Oral and Maxillofacial Surgery, Faculty of Oral and Dental Medicine, Cairo University, Egypt, **Tel.:** 0503758753, **E-mail:** abuelnaga_dentist@yahoo.com.

ISSN: 2090-097X, May 2018, Vol. 9, No.2

INTRODUCTION

Successful dental implant placement for restoration depends on the dimensions of alveolar bone available. Therefore we perform hard tissue ridge augmentation to overcome alveolar bone defect before dental implant placement and restoration^[1, 2].

There is no single ideal technique or graft material but rather an increasing number of materials and methods to be used in individualized approaches to ridge reconstruction^[2]. Different techniques have been used in reconstruction of the deficient ridge including various vertical guided bone regeneration procedures, alveolar distraction osteogenesis, onlay bone grafting, and inlay^[3, 4].

Using particulate bone grafting material will increase both height and width of alveolar ridge, allows easy contouring but requires a membrane to stabilize the graft

and to avoid the undesired soft tissue cells ingrowth. In contrast to particulate grafting materials, block grafts provide stable fixation using osteosynthesis screws, but will restore either height or width^[5].

The stabilization of the block on the recipient bed has been considered critical factor for graft success. To achieve this, the blocks have to be placed several times on the defect to test the fitness and have to be removed again to be trimmed and adapted. This process increase the risk of contamination intraorally by saliva or extraorally by the surgeon. For this reason, the longer the adaptation phase, the more likely the contamination of the graft and this is considered one of the main causes of block grafts failure^[5].

To avoid block graft infection, data taken from a computerized tomographic (CT) scan can be used to shape a precise 3D bone graft using a computer aided design-computer aided manufacturing (CAD-CAM) system. In this way, the bone block can be transferred directly from

its sterile packaging to the receiving site without the need to be adapted.

The aim of this study is to evaluate clinically and radiographically the volume changes of alveolar ridge grafting using customized Xenogenic bone graft and compare it with the standard particulate Xenogenic bone grafting with titanium mesh in restoring both vertical and horizontal alveolar bone deficiency.

PATIENTS AND METHODS

A total of 12 patients were randomly selected in this study, Group I (Test Group) comprised 6 patients in which alveolar posterior mandibular ridge augmentation was performed utilizing customized xenogenic bone graft Smartbone (IBI S.A., Switzerland). Group II (Control Group) comprised 6 patients in which particulate Xenogenic bone (Smart bone, IBI S.A., Switzerland) grafting to posterior mandibular ridge with titanium mesh was performed. All patients requiring augmentation and had a horizontal and vertical defects ≥ 3 mm in the mandibular ridge assessed radiographically using CBCT. All patients were selected from outpatient clinic of the Oral and Maxillofacial Surgery Department, Faculty of Oral and Dental Medicine, Cairo University. All surgical procedures were performed by the same surgeon between July 2015 and July 2017.

Group I (Test Group) - Planning and manufacturing of Customized bone graft.

A preliminary CBCT scan was performed to evaluate alveolar residual bone anatomy and plan the implant positioning. The CT scan was saved in DICOM format. DICOM file was opened in the software program Mimics version 15.01 (Materialise NV, Leuven, Belgium) then thresholding is performed and a 3D reformatted scan of the deficient ridge is generated on which a 3D sphere was planned to restore the deficient alveolar ridge (Figure 1) then the subtraction was performed. Then the resulted part was contoured and smoothed using the software 3Matic version 7.01 (Materialise NV) (Figure 2).

These digital structure, provided a 3D simulation about the morphology of the bone graft (Figure 3), after which it was saved as an Stl file and E-mailed to the company IBI

S.A (Switzerland) for milling of the customized bone graft (Figure 4) .

Then, the graft was milled out of a single block of bone. After cleaning, packaging, and sterilization using ethylene oxide gas then complete forced 24h degassing was applied after sterilization cycles to completely remove any residual gas, the individual bone block was sent back to the surgeon Figure (5).

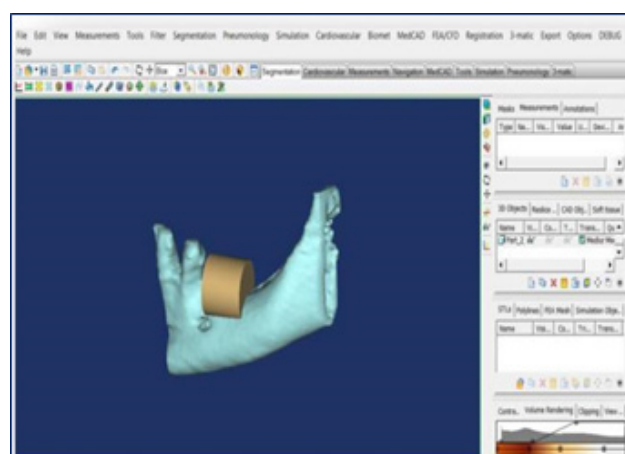


Fig. 1: Showing 3D sphere was drawn directly on the 3D surface of the deficient ridge using the software program Mimics version 15.01 (Materialise NV).

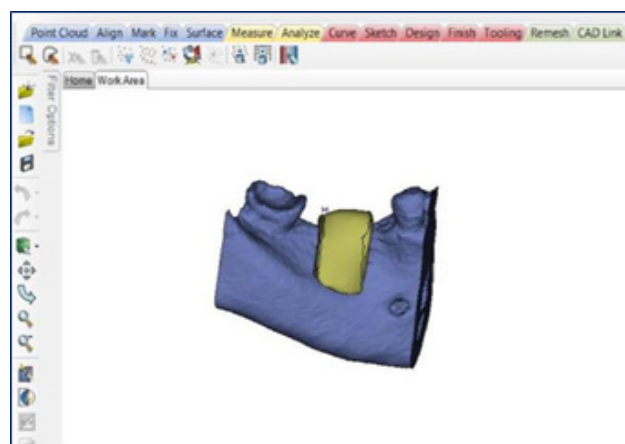


Fig. 2: showing the virtual grafted area after being contoured and smoothed using the software 3Matic version 7.01 (Materialise NV).

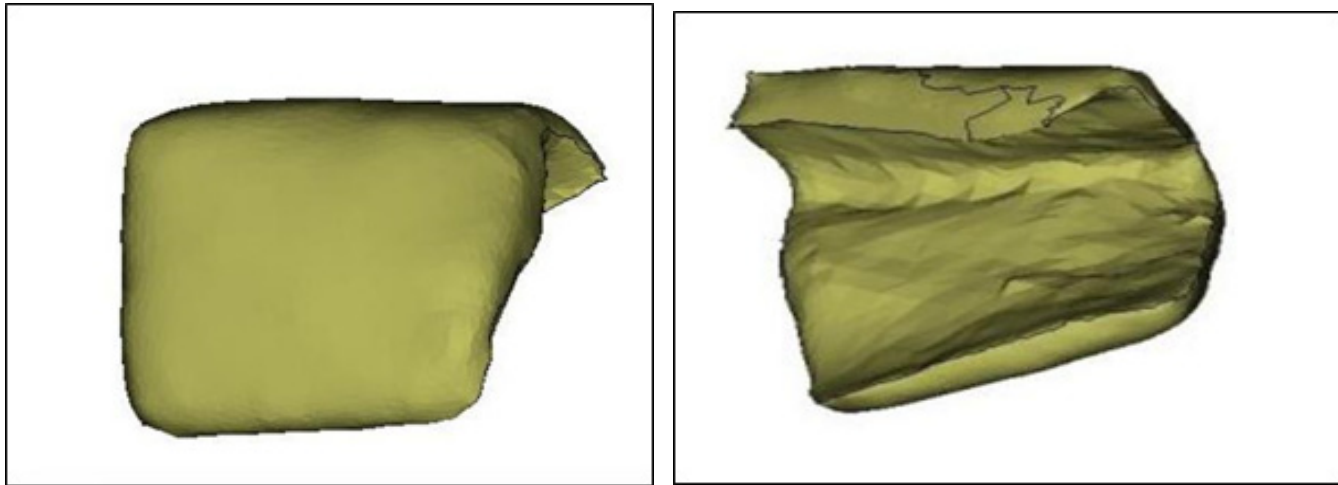


Fig. 3: showing the virtual grafted area (outer surface and inner surface) after being contoured and smoothed using the software 3Matic version 7.01 (Materialise NV).



Fig. 4: Showing milling of Xenogenic bone block (Smart Bone)

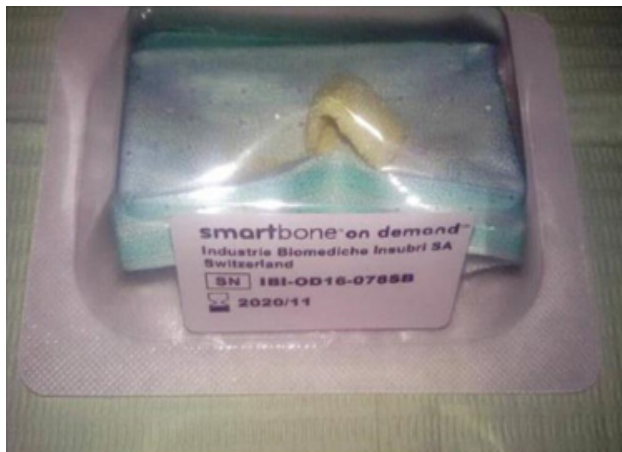

Fig. 5: Showing packed and sterilized CAD/CAM Xenogenic bone graft (Smart bone).

Surgical procedure:

Patients were randomly selected for both groups. The patients were instructed to rinse their mouth with Orovex* for 2 minutes just before surgery. All procedures were performed under sterile conditions. Local anesthetic solution Ubištesin TM forte** with vasoconstrictor epinephrine 1:100,000 was injected as inferior alveolar nerve block and infiltration into operative site for anesthesia and hemostasis.

The deficient bone site is exposed by making full-thickness pyramidal flap. A mid-crestal incision was made at the recipient site and vertical incision was performed on the buccal side then a full-thickness flap was raised to the mucogingival junction. After separating the periosteum, the preparation of the flap was continued. The lingual and buccal subperiosteal tissue was carefully elevated to gain adequate visibility of the recipient site without applying tension to the ipsilateral mental nerve. The recipient site was scored using diamond round bur (1 mm diameter) to increase the vascularity to the bed of the graft (Fig 6).

For Group I: The xenogenic CAD/CAM bone block (Smartbone) was snapped in place and fitted exactly onto the recipient site then it was rigidly fixed on the mandibular ridge with 1.5mm diameter microscrews (Lorenz system, Biomet). The heads of the screws were countersunk even to the block surface. (Fig 7 - 8).

For Group II: the titanium mesh was adapted onto the recipient site and Xenogenic bone powder (Smartbone) 0.25 – 1mm particle size, bone powder was packed

under the titanium mesh and titanium mesh was fixed to surrounding bone with 1.5mm diameter microscrews (Lorenz system, Biomet) Figure (9).

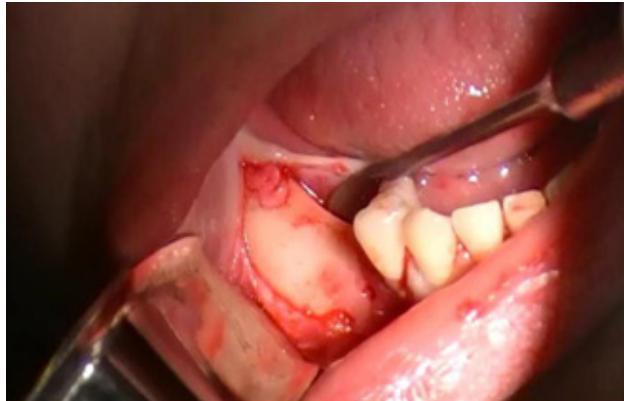

Fig. 6: Showing the raised mandibular flap.




Fig. 7: Showing the CAD/CAM xenogenic bone graft (SmartBone®).

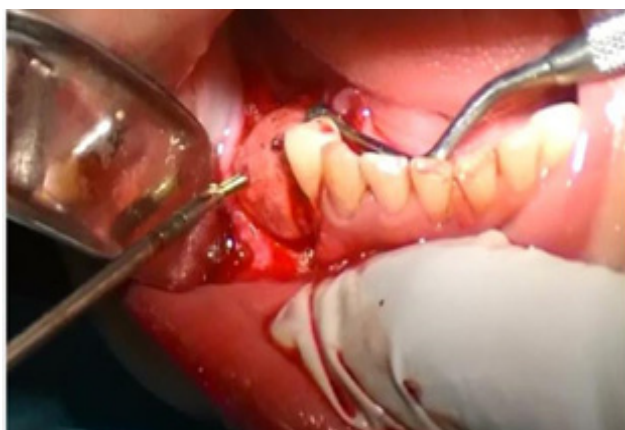

Fig. 8: Showing placement of micro screw for fixation of customized bone graft.

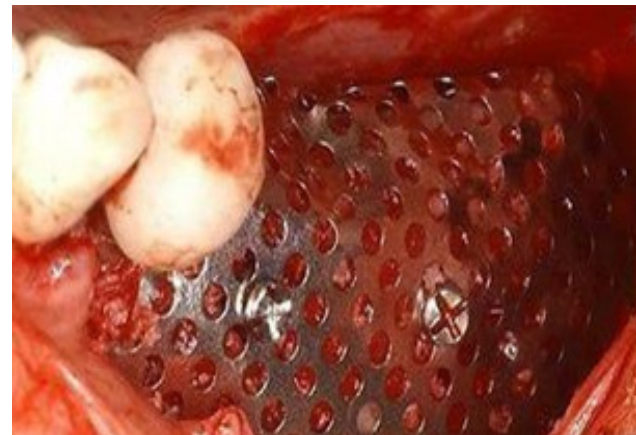

Fig. 9: Titanium mesh with xenogenic bone graft

Scoring of the buccal periosteum with no.15 blade at a level below the bone graft allowing for tension free closure of the wound with maintenance of the periosteal cover of the graft. The flaps were repositioned and sutured passively with a combination of mattress and running 3-0 Polyglycolic acid (PGA) sutures. Postoperative follow-up was carried out every week during the first month, and then every month for 3 months.

II- Radiographic Examination:

Radiographic examination was performed preoperatively and 4 months postoperatively by CBCT scan with the same parameters for both Groups I and II. CBCT scan was used to assess the bone volume and density of bone formed.

Volumetric assessment of the newly formed bone:

The Cone beam C.T was used for volumetric assessment of the defective alveolar ridge and to measure the amount of bone formed in the grafted area at the end of follow-up period. A horizontal reference line was taken from apex of neighboring teeth to standardize data retrieved from radiographs using CBCT scans. From the reference line the available bone was outlined in all coronal cuts in the preoperative and postoperative CBCT scans to measure the bone volume.

The defective alveolar ridge was traced on each coronal cut of 1mm thickness, following the estimated outline of the labial and lingual cortices using OnDemand 3D Application (V. 1.0.10) Software. To determine the volume of the bone (V), the surface area of the grafted area was measured in all CBCT slices; the outline of the bone on each CBCT slice was plotted, and the surface area (A) was automatically calculated by software program

OnDemand 3D Application (V. 1.0.10).

The bone volume in the region of interest of the CBCT scan was calculated by multiplication of the surface area (A) and the height (h), which is similar to the defective bone area thickness (Figure 11). The average volume of the whole defective bone area (V) results from the sum of all measured single volumes of CBCT scans: $V = \sum A \times h$, then average mean values of bone volume were calculated. The preoperative volume measurements were recorded as "base line values" and was used to calculate the volume of the defective alveolar ridge according to Uchida et al. and Smolka et al.^[6, 7]

These measurements were taken from CBCT scans exposed preoperatively and 4 months post-operative for both groups I and II. (Figure 12). [Bone volume 4 months (-) Base line values] were calculated, then volume of the newly formed bone were calculated.

**Densitometric analysis of the newly formed bone:
Bone density calculation:**

Densitometric analysis of the grafted area 4 months post-operatively in both groups were performed and compared with native bone. Bone density was assessed in standardized coronal cuts of 1 mm thickness through the grafted area at 4 months post-operative CBCT, using

OnDemand3DApp (V. 1.0.10) Software. Analysis of bone density was performed by taking two random readings in each cut using two square shapes in each cut, one at native bone and other one at the newly formed bone with pre-specified area of 10 pixels X 10 pixels, then an average mean value was calculated by OnDemand3DApp (V. 1.0.10) Software in Hounsfield units (HU) (Figure 13).

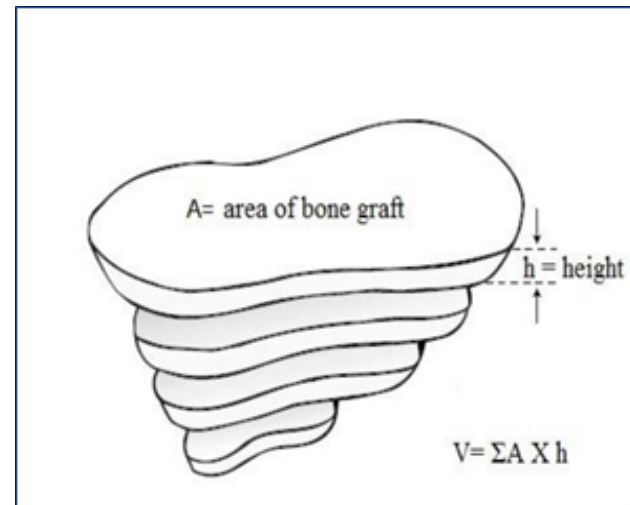


Fig. 10: Schematic drawing of volumetric measurements: the volume of defective bone area is calculated by multiplying the area (A) and the CT slice thickness (h).

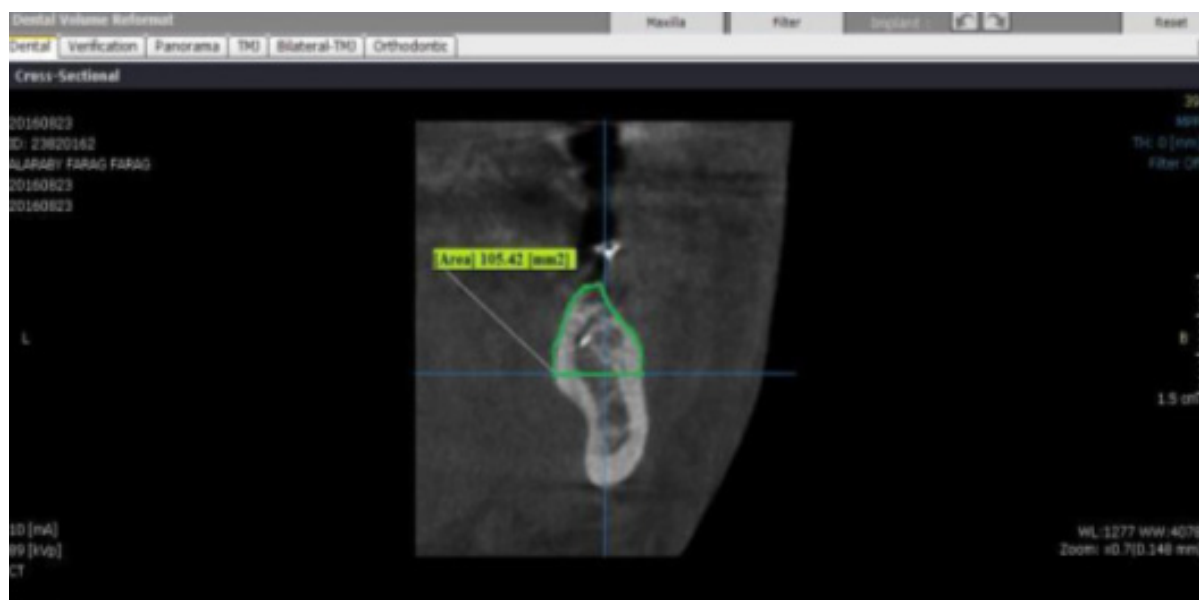


Fig. 11: Showing surface areas measurements of alveolar bone ridge defect.

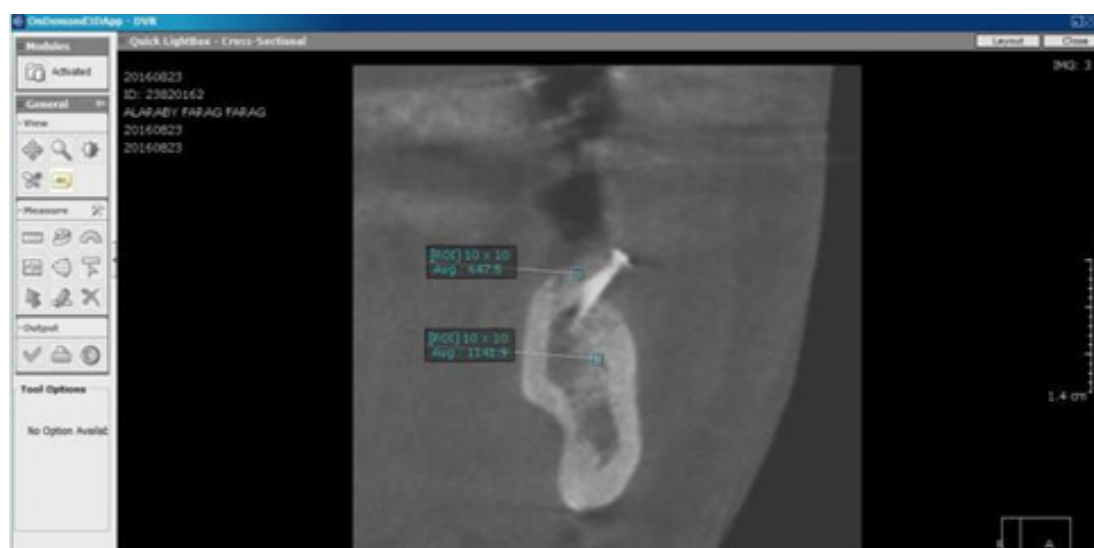

Fig. 12: Bone density assessment using 10 pixels X 10 pixels rectangle shape.

Statistical methods:

Data were analyzed using IBM SPSS advanced statistics (Statistical Package for Social Sciences), version 21 (SPSS Inc., Chicago, IL). Data were explored for normality using Kolmogrov-Smirnov test and Shapiro-Wilkes test. Numerical data were described as mean and Standard deviation. Categorical data were described as number and percentage. Comparisons over time (pre and post augmentation for each group) were done by paired t test. Comparison of the 2 groups were performed using T

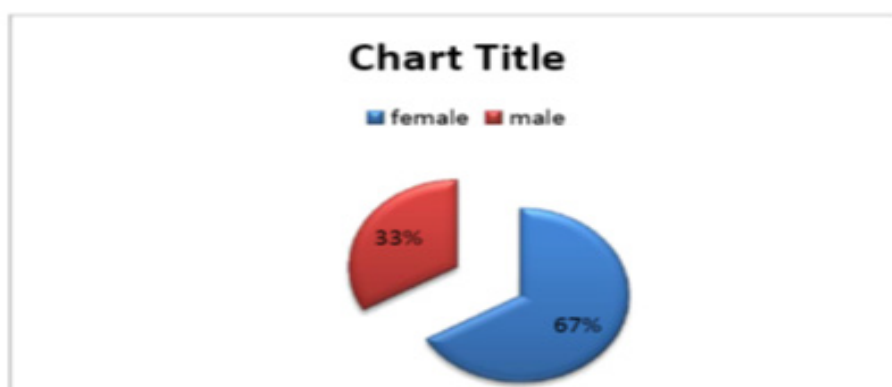
test. Adjustments of p value were done using the Bonferroni method for multiple testing. A P-value less than or equal to 0.05 were considered statistically significant.

RESULTS

A total of 12 patients, 8 females (66.7 %) and 4 males (33.3 %) with mandibular alveolar ridge defects were included in this study. All patients were included for statistical analysis.

Table 1: The descriptive statistics of patients' sex and age.

	Mean	SD	Median	Minimum	Maximum
Age	34	7.4	34.0	23	42
Gender	Frequency		Percent		
Female	8		66.7		
Male	4		33.3		



Graph 1: showing patients' descriptive distribution.

Clinical observations:

There were no significant clinical complications observed. The immediate post-operative follow-up showed mild facial swelling, local edema and/or erythema were common and resolved within 1 week. No infection or necrosis of the flap was observed in any of the cases (figure 14). Flap dehiscence with partial graft and mesh exposure (not exceeding 7mm in width) was observed in 2 cases of the control group at 8 and 14 weeks. These patient were instructed to use Orovex* mouth wash and follow-up with irrigation twice a week.

At the end of the follow-up period, neither signs of infection nor evidence of fibrosis or scarring were noted in bone. Four months after surgery, re-exposure of the augmented sites was performed. The grafted bone showed good integration and good vascularization with no signs of necrosis or mobility but softer in consistency on drilling for implant placement (Figure 15).

Radiographic results:

At the end of the 4 months follow-up period, the post-operative CBCT scans for both Group I and showed newly formed bone and increase in alveolar bone dimensions in most cases except 2 cases from the control group where we had the mesh exposure. The augmented alveolar ridges showed good maturation of bone graft on the follow up CBCT scans, with evidence of normal bony architecture Figure (16).

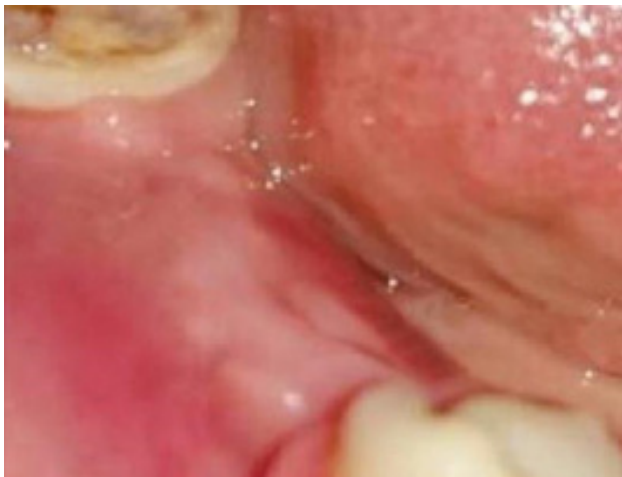

Fig. 13: Showing postoperative augmented ridge.

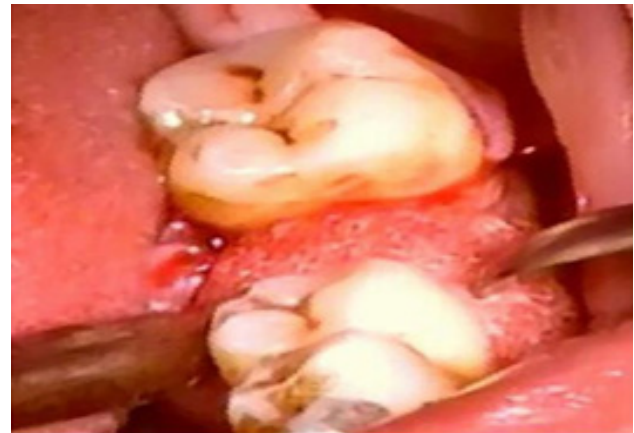


Fig. 14: Showing good integration and vascularization of the graft after 4 months

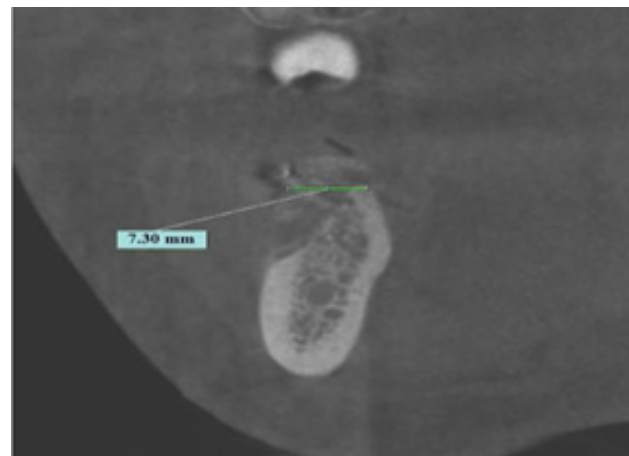


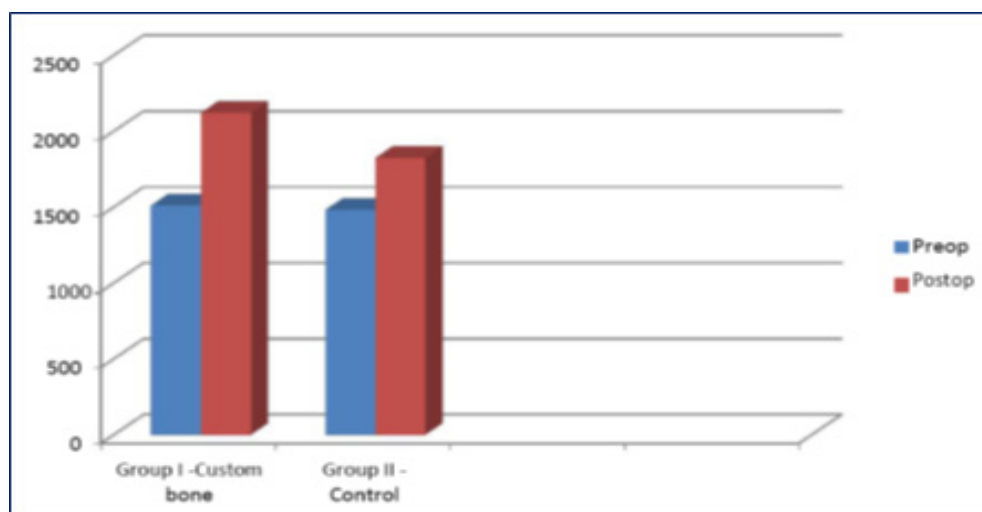
Fig. 15: Showing post-operative CBCT with bone grafting with CAD/CAM xenogenic bone

1. Radiographic evaluation of Alveolar ridge volume measurements:

Descriptive statistics of alveolar ridge volume measured by OnDemand3DApp software from CBCT scan are summarized in (Table 2) comparing the postoperative to preoperative alveolar bone volume changes. There was increase in bone volume by 40% in the area of the newly formed bone in Group I (Customized bone). Paired sample t-test showed a statistically significant increase of bone volume four months post-operatively as compared to preoperative bone volume in Group I (Customized bone) (P value =0.001) (Graph.2).

There was increase in bone volume by 23% in the area of the newly formed bone in Group II (Control Group). Paired sample t-test showed a statistically significant increase of bone volume four months post-operatively as compared to preoperative in Group II (Control

Group) (P value =0.001). Comparing the postoperative bone volume in Group I (Customized bone) with the postoperative bone volume in Group II (Control Group) showed a statistically significant difference (P value = 0.005).



Graph. 2: Showing alveolar ridge pre-operative volume and alveolar ridge post-operative volume in both Group I (Custom bone) and Group II (Control Group).

Table 2: Comparison between pre and postoperative according to alveolar ridge volume.

Volume	Group I (Custom bone)		Group II (Control Group)	
	Preoperative	Postoperative		
Mean	1511.0	2122.0	1482.5	1824.5
% newly formed bone		40%	23%	
P value		0.001*	0.001*	

* P value <0.05 is considered statistically significant

2- Density:-

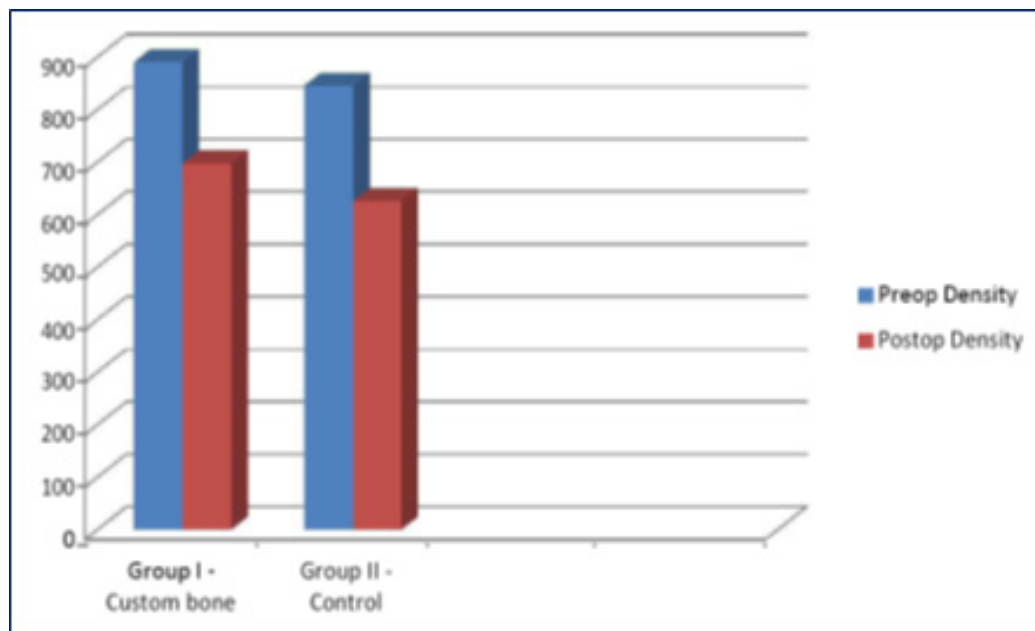
Descriptive statistics of alveolar bone density measured by OnDemand3DApp software from CBCT scan 4 months post-operatively are shown in (Table2).

Student t-test showed the density of the newly formed bone in the augmented area in Group I (Customized bone) showed statistical significance when compared to

the density of the native bone density four months post-operatively ($p=0.04$). Similarly, Group II control Group showed statistical significant difference when compared to the density of the native bone density four months post-operatively ($p= 0.03$). However, there was no statistically significant difference between the density of newly formed bone in Group I (customized bone) when compared with the control Group II (Particulate with mesh) ($p > 0.05$).

Table 3: Showing descriptive statistical comparison between bone density native and grafted area in Both Group I (Custom bone) and Group II (Control).

Density	Group I		Group II	
	Native bone	Customized	Native bone	Customized
Mean	890.3	697.8	845.4	625.4
P value	P= 0.03*		P=0.04*	



Graph 3: Showing means density of native bone versus mean density of the newly formed bone in both Group I (Custom bone) and Group II (Control Group).

DISCUSSION

In the treatment of the defective mandibular ridge, xenogenic bone graft is considered an effective alternative for ridge augmentation. However, xenogenic bone grafts were more technique sensitive than autogenous bone grafts and more liable to infection, which necessitated careful surgical technique and follow-up^[8].

PiStilli *et al.* in his study in 2011 reconstructed an atrophic maxilla with an equine bone block. This study shows ideal clinical and histological results, eight months after augmentation procedure, histological analysis revealed large areas of bone remodeling and a huge amount of graft particles and strong osteoblastic activity, with bone marrow with new blood vessels and cells. After three months the equine bone block was no longer distinct from the innate bone^[9].

Nissan J *et al.* used cancellous freeze-dried block allografts for ridge augmentation in the anterior deficient maxillary ridge followed by placement of dental implants in thirty-one successive patients. They reported that implant placement in the anterior maxilla after augmentation with freeze-dried cancellous block allografts can lead to successful implant osseointegration^[10].

Leonetti A reported that using allogenic bone blocks delivers effective new bone fill for dental implant. Monjea A and Wanga H described that allogenic and xenogenic bone blocks represent a valuable alternative to autogenous bone in ridge augmentation. They stated also that the evidence supporting xenogenic block graft usage remains minimal; so more long-term human studies are needed to confirm their effectiveness^[11].

Gheno E *et al.* considered using xenogenic bone

blocks mixed with autologous concentrated growth factors (CGF) in alveolar ridge augmentation as a practical option in bone regeneration surgery and can be achieved in the dental clinic^[12]. SmartBone® (IBI S.A., Switzerland) used in our study is produced by combining xenogenic bone constructions with bioactive polymers and cell nutrients. This new theory of biomaterial assembly allows the patient's cells to grow rapidly and efficiently into SmartBone while its biopolymers degrade, providing seamless integration and osteogenesis. Bioactive polymers give SmartBone® great loading resistance, high volumetric stability; the polymers guard the bone from premature resorption and high tenacity to screws fixation.

Pertici G reported that a composite graft made of natural mineral matrix (calcium HA), synthetic polymer coating poly (L-lactide-co-ε-caprolactone) (PLCL) and polysaccharides was developed. The purpose behind coating mineral matrix with PLCL and polysaccharides comes from the necessity to have higher mechanical properties together with suitable microstructure and to improve hydrophilicity for good cell adhesion. The fabricated bone graft exhibited regular microstructure with an average 27% porosity^[13].

Grecchi F *et al.* used Custom-made SmartBone® in reconstruction of zygomatic bone and they reported that SmartBone® grafts have shown to be easy to manage and biocompatible, showing excellent final results. 3 Dimensional reconstruction of the defect greatly helps in the surgical planning and reduces the surgical time^[14].

Infection is deliberated as the main complication that happens with the usage of allografts or xenografts as Jacotti M *et al* specified. Chaushu reported that infection of the bone grafted site occurred in 18 (13%) of 137 bone blocks. In 7 (39%) of the 18 infected blocks, total graft failure was established, and in 4 (22%) of the 18 partial graft failure was established^[15, 16].

Chaushu *et al.* declared that there is no significant relationship between the potential risk factors for complications and patient age or sex. Complications occurred significantly more in the mandible than the maxilla. The incidence of more than one complication significantly increased the risk of infection and graft failure. Precisely, combined membrane uncoverage with incision line opening resulted in infection in 44% of cases and into total graft failure in 17%. He reported that the usage of the cancellous block graft was not only the cause of graft failure but also technical issues^[16].

Shaping or trimming the graft to adapt it to the recipient site is one of the causes of infection. Usually, the block is shaped during surgery with a bur, until it is adapted to the defected site. In this procedure, the bone block is subjected to numerous possible sources of contamination deriving from prolonged contact with the surgeon gloves, the saliva

of the patient and the surgical instruments^[8].

In our study, we used data from a CT scan to create a customised bone graft by CAD/CAM system. Through the CAD-CAM method, grafts were created starting from the CT and customized according to each patient data. The bone graft comes from the company in sterile packaging and only needs to be fixed to the recipient site and this reduces any probability of contamination.

Garagiola U *et al.* used CAD/CAM methods for preparing Hydroxyapatite frameworks for alveolar ridge augmentation the premolar area. They stated that CAD/CAM methods may improve graft stability and decrease operating time^[17].

CAD/CAM grafts used in our study did not need to be shaped chair-side so they were adapted well and fitted perfectly without any chair-side adaptation so surgical time was reduced as the time of shaping and trimming was eliminated. Reducing time and maximize the adaption of the graft is critical to its integration with the surrounding bone. This is in contrast to the bending of the titanium mesh in the control group and packing of particulate xenogenic bone under the mesh, which lacks good stability compared with customized bone blocks^[8, 15].

As the customized bone graft did not need manual shaping or trimming, this reduced the stress on surgical tissues and reduced dehiscence of the wound, decreasing all postoperative complications. This technique is substantially simple, and so it is appropriate for less experienced surgeon.

Schlee M, Rothamel D, stated their use of customized allogenic bone blocks in mandibular posterior alveolar ridge augmentation for 3 patients. Healing was observed in 2 of the 3 cases. Histological evaluation showed new bone formation, and both patient satisfaction and long-term stability were considered excellent. They concluded that the application of individual CAD allografts decreased patient morbidity, reduced surgery time^[18].

In our study, augmentation of mandibular alveolar ridge defects using customized xenogenic bone graft Smartbone (IBI S.A., Switzerland) was evaluated clinically and radiographically. Clinically; this technique provides excellent adaptation to the recipient site, easy application of the graft, reducing the surgery time and postoperative complications. Also, there was 40% increase in postoperative bone volume in Group I (custom bone) compared with 23% only in Group II (control Group).

Jacotti M *et al.* described that using a customized bone block for alveolar ridge augmentation is a valuable alternative to autograft. Their study showed 6.09, 7.36, and 8.08 mm (mean, 7.18 mm) of total horizontal bone gain was observed at sites 6, 12, and 18 mm posterior to

the right mental foramen, respectively after using onlay allograft created with CAD-CAM procedure in posterior alveolar ridge augmentation^[8].

In our study, radiological assessment is considered one of the most consistent methods in assessing amount of bone regeneration and identifying the amount of new bone and resorption rate of the graft. Using of CBCT with OnDemand3DApplication (V. 1.0.10) software to measure bone volume in the jaws had been well described. This method had been described in previous studies in CT for sinus augmentation scans and we applied the same concept in CBCT scans. The final outcome of mean bone volume after ridge augmentation in our study was 2122 mm³ instead of 1511mm³ preoperatively. So the bone volume gained of bone graft was 605mm³.

Radiographic findings in our study revealed that the density of the new bone was comparable to the native bone. No statistical significant difference was found in postoperative bone density between Group I (Custom bone) and Group II (Control Group).

Schlee M, described that results obtained with using customized allogenic bone block were comparable to those attained with autologous bone grafts. He established that after using CAD/CAM allogenic bone graft in mandibular ridge augmentation, the resorption rate was negligible after 6 months and no additional augmentation was needed^[19].

Thus, the use of customized xenogenic bone graft could be considered as a good effective treatment modality for defective alveolar ridge augmentation of the mandibular ridge.

CONCLUSION

Based on the outcome of our study, it can be concluded that (I) Customized xenogenic bone graft is considered an effective modality for augmentation of mandibular ridge defects comparable to conventional techniques. (II) Customized xenogenic bone graft provides good stability with an ideal shape of the graft.

CONFLICT OF INTEREST

There are no conflicts of interest.

REFERENCES

1. Toscano N, Nicholas Shumaker B, Holtzclaw D. The Art of Block Grafting A Review of the Surgical Protocol for Reconstruction of Alveolar Ridge Deficiency. *J Implant Adv Clin Dent.* 2010; 45(2): 45-65.
 2. Sheikh Z, Sima C, Glogauer M. Bone replacement materials and techniques used for achieving vertical alveolar bone augmentation. *Materials (Basel).* 2015; 8(6): 2953-2993.
 3. Chiapasco M, Zaniboni M, Rimondini L. Autogenous onlay bone grafts vs. alveolar distraction osteogenesis for the correction of vertically deficient edentulous ridges: A 2-4-year prospective study on humans. *Clin Oral Implants Res.* 2007; 18(4): 432-440.
 4. Felice P, Piattelli A, Iezzi G, Degidi M, Marchetti C. Reconstruction of an atrophied posterior mandible with the inlay technique and inorganic bovine bone block: a case report. *Int J Periodontics Restorative Dent.* 2010; 30(6): 583-591.
 5. Proussaefs P, Lozada J, Kleinman A, Rohrer MD. The use of ramus autogenous block grafts for vertical alveolar ridge augmentation and implant placement: a pilot study. *Int J Oral Maxillofac Implants.* 2002; 17(2): 238-248.
 6. Uchida Y, Goto M, Katsuki T, Soejima Y. Measurement of maxillary sinus volume using computerized tomographic images. *Int J Oral Maxillofac Implants.* 1998; 13(6): 811-818.
 7. Smolka W, Eggenesperger N, Carollo V, Ozdoba C, Iizuka T. Changes in the volume and density of calvarial split bone grafts after alveolar ridge augmentation. *Clin Oral Implants Res.* 2006; 17(2): 149-155.
 8. Jacotti M, Barausse C, Felice P. Posterior Atrophic Mandible Rehabilitation With Onlay Allograft Created With CAD-CAM Procedure. *Implant Dent.* 2014; 23(1): 22-28.
 9. Pistilli R, Checchi V, Iezzi G, Nisii A, Pecora CN, Felice P. Augmentation of atrophic maxilla with equine-derived heterologous bone block grafts for rehabilitation with fixed implant prosthesis: a clinical case. *Rivista Italiana di Stomatologia* 2011,(1)1: 12.
 10. Nissan J, Mardinger O, Calderon S, Romanos GE, Chaushu G. Cancellous Bone Block Allografts for the Augmentation of the Anterior Atrophic Maxilla. *Clin Implant Dent Relat Res.* 2011; 13(2): 104-111.
 11. Leonetti J a, Koup R. Localized maxillary ridge augmentation with a block allograft for dental implant placement: case reports. *Implant Dent.*2003; 12(3): 217-226.
 12. Gheno E, Palermo A, Rodella LF, Buffoli B.
-

- The effectiveness of the use of xenogeneic bone blocks mixed with autologous Concentrated Growth Factors (CGF) in bone regeneration techniques: A case series. *J Osseointegration*. 2014; 6(2): 37-42.
13. Jiang L, Zhang J, Pertici G, *et al.* Composite Polymer-Coated Mineral Grafts for Bone Regeneration: Material Characterization and Model Study. *Ann oral Maxillofac Surg*. 2014; 2(1): 1-7. doi:10.1016/S0142-9612(00)00330-6.
 14. Grecchi F, Perale G, Candotto V, Busato A, Pascali M, Carinci F. Reconstruction of the zygomatic bone with smartbone: Case report. *J Biol Regul Homeost Agents*. 2015; 29(3): 42-47.
 15. Monje A, Wang H. Biological and physical properties of bone block grafting biomaterials for alveolar ridge augmentation: *J Oral Science Rehab.*, 2017; 3(1)18-30.
 16. Chaushu A, Nissan J. The Use of Cancellous Bone-Block Allograft for Reconstruction of the Atrophic Alveolar Ridge. *Tissue Engineering and Regenerative Medicine* 2012,(4) 239- 258.
 17. Garagiola U, Grigolato R, Soldo R, *et al.* Computer-aided design/computer-aided manufacturing of hydroxyapatite scaffolds for bone reconstruction in jawbone atrophy: a systematic review and case report. *Maxillofac Plast Reconstr Surg*. 2016;38(1):2. doi:10.1186/s409027-0048-015-.
 18. Schlee M, Rothamel D. Ridge Augmentation Using Customized Allogenic Bone Blocks. *Implant Dent*. 2013; 22(3): 212-218.
 19. Schlee M, Rothamel D. Ridge augmentation using customized allogenic bone blocks: proof of concept and histological findings *Implant Dent*. 2013 Jun; 22 (3): 212-8.